

Clinical Experience With Fourier- domain OCT

The RTVue offers high-quality images with versatile features.

BY JENNIFER I. LIM, MD

Optical coherence tomography (OCT), developed by Huang and colleagues¹ as a non-invasive imaging tool, has become indispensable in the armamentarium of retinal physicians. The OCT is an outstanding example of applied physics in medicine. This article will discuss the technology and highlight the advantages of the Optovue RTVue FD-OCT imaging system (Optovue, Inc., Fremont, CA).

BACKGROUND

The RTVue FD-OCT system performs 26,000 A-scans per second, 65 times faster than the Stratus OCT (Carl Zeiss Meditec, Dublin, CA). This Fourier-domain (FD) OCT system also employs a higher spectral bandwidth light source (as do other FD-OCT systems), which provides a finer axial resolution of 5 μm —a twofold improvement over the Stratus. The RTVue, similar to other FD OCT machines, utilizes a superluminescent diode that is compact, reliable, and more economical than the sources required for ultra-high resolution OCT. The RTVue was the first US Food and Drug Administration-approved FD-OCT system.

The RTVue has several unique features encompassing imaging and analysis and technological capability. One of the major strengths of the system is the software for analysis of the data. The RTVue has progression analysis and asymmetry analysis available. The progression analysis report can review and analyze the results of four different visits, as well as compare the left-to-right-eye results.

The OCT is an outstanding example of applied physics in medicine.

Fourier-domain OCT systems, unlike time-domain (TD) OCT systems, harbor varying signal strengths from the top of the scan to the bottom of the scan. The Optovue RTVue takes advantage of this difference by incorporating a “vitreous mode” and a “choroidal mode.” In the vitreous mode, the signal strength from the vitreoretinal scanned region is enhanced vs the retinochoroidal portions of the scan. This is useful for detection of epiretinal membranes or vitreomacular traction. In the choroidal mode, the signal from the retinochoroidal portion of the scanned region is enhanced as compared to the vitreoretinal portion. This choroidal mode is useful for detection of choroidal neovascularization and layers such as the RPE. Thus, one selects which mode to use based upon the diagnosis.

IMAGE QUALITY

The RTVue images are said to be “speckle-less.” The Optovue system uses frame-averaging algorithms that increase the clarity of the OCT image. This is achieved by automatic averaging of images. Sixteen frames are averaged with each captured scan (unaveraged images can also be reviewed, as both unaveraged and averaged

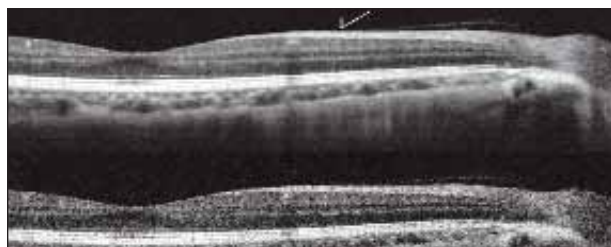


Figure 1. Examples of averaged image (top, standard RTVue) and a unaveraged retinal image (bottom). The boundary of tissue and blood vessel walls are more well-defined in the averaged image. Note that a small retinal blood vessel (arrow) located half-way between disk and fovea is visible only in the averaged image. The large blood vessel (located to the left of the small vessels and causing shadowing posteriorly) is seen in both unaveraged and averaged image.

images are stored in the system). The RTVue has good algorithms for registration and averaging. The averaged image has low image noise and a speckle-less OCT image. The Spectralis HRA+OCT (Heidelberg Engineering, Heidelberg, Germany) also has good algorithms for averaging and registration. The 3D OCT-1000 (Topcon Medical Systems, Paramus, NJ) system also averages images. Figure 1 shows the detection of small retinal vessels visible only on the averaged image as opposed to the nonaveraged image on the RTVue. Future software on the MM5 program (Optovue, Inc.) will enable “en face” blood vessel registration of images.

With respect to retinal imaging, there are some unique features of the Optovue RTVue system. In addition to the line scan and crosshair scan capabilities, the RTVue system has a MM5 grid scan that is unique. This unique scan is completed in 0.7 seconds. The MM5 covers a 5-mm-grid area. For the central 3-mm-area of this grid, the scans are spaced 0.25-mm apart. In the 3-mm- to 5-mm-region of this area, the scans are spaced 0.5 mm apart. The analysis program can be used on the MM5 to generate retinal thickness data (Figure 2).

REGISTRATION AND ANALYSIS

The new version of the MM5 map will allow for even better registration. The new software allows en face imaging of retinal blood vessels. This will enable future scans to be registered with respect to the retinal vessel architecture (Figure 3).

Analysis of the MM5 map occurs automatically. The analysis includes creation of the inner retinal thickness map, outer retinal layer thickness map, and determination of the amount of retinal pigment epithelial elevation. The outer retinal thickness map is a unique feature. This may prove useful clinically in following patients with outer reti-

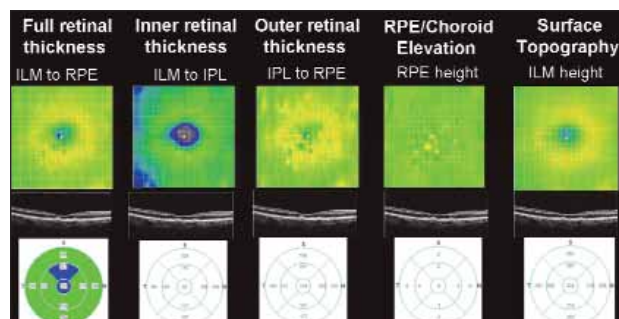


Figure 2. MM5 maps incorporate 19,496 A-scans (pixels) in a 750 milliseconds. The area covered is 5x5 mm (grid pattern). Note the analysis program generates retinal thickness measurement for the different retinal layers.

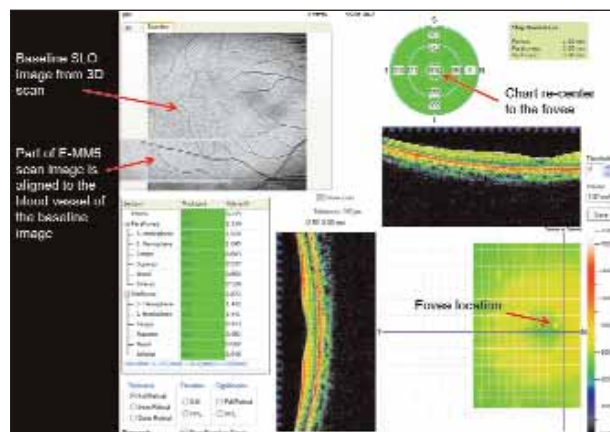


Figure 3. E-MM5 registration shows en face retinal vessels. This allows for more exact registration of MM5 scans by aligning the EMM5 scan with the retinal vessels from the baseline SLO-OCT-like image.

nal degeneration such as retinitis pigmentosa.

The MM5 also allows specific volume measurements of the retina above certain thresholds. The new software (available June 2008 and provided by the company) will enable one to specify a retinal thickness and determine where the retinal thickness exceeds this measurement. The volume of this area of the retina can be determined. For example, in a patient with diabetic macular edema, one can then visualize where the retina is thicker than 250 μm and determine the retinal volume of that thickened retina (Figure 4). This would be useful in evaluating patients (providing an objective measurement) with macular edema.

Although the RTVue can also perform a 3-D retina scan (composed of 101 B-scans, each containing 512 A-scans) over a 4x4-mm area, it is more difficult to analyze the retinal thickness due to the density of the scans. There is also a 2-second eye motion artifact as with any 3-D scan taken with an OCT system without eye

(Image courtesy of Dr. Jay Wei, Optovue Inc.)

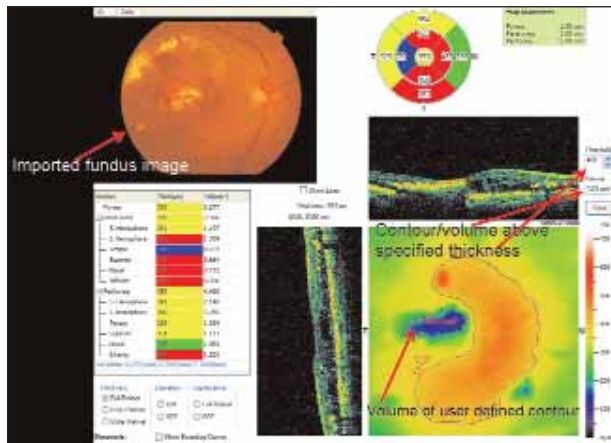


Figure 4. A diabetic macular edema eye is shown with the imported fundus image and the MM5 analyzed scan. The volumetric measurement program was used to determine the contour of elevated retina above the chosen threshold of 400 µm.

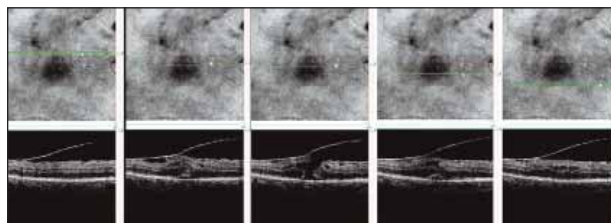


Figure 5. Three-dimensional imaging is useful for determining the extent of involvement over a large area. Top: En face view of retinal surface from 3-D scan. Bottom: B-scan from corresponding location (green line) on the retinal image.

tracking capabilities. In contrast, the MM5 is not as subject to motion as the scan time is 0.7 seconds. The 3-D retina scan can generate a scanning laser ophthalmoscopy-like fundus image (Figure 5).

NORMATIVE DATABASE

The RTVue was the first OCT system to have a normative database. In phase 1, (released 2007), more than 300 eyes were used. In phase 2 (to be released around the American Academy of Ophthalmology meeting in Atlanta this year), risk-specific normative groups will be included (white, black, Latino, Chinese, Japanese, and East Indian). This database includes data on optic discs, thicknesses of the ganglion cell complex layer (inner retinal layer), outer retinal layer, nerve fiber layer (NFL), and outer retinal layer, as well as data on retinal pigment epithelium height maps. These data are useful in analyzing the patient's data.

I have also used the RTVue system to evaluate the retinal ultrastructure and compare eyes with retinal dystrophy to normal eyes. The outer retinal layer was

found to be 45% thinner in the dystrophy as compared with the normals.²

ANTERIOR-SEGMENT IMAGING

In addition to these posterior segment features, the RTVue can also image the anterior segment. The RTVue is the only FD OCT system capable of performing retinal and anterior-segment OCTs. Applications for glaucoma include determination of optic nerve morphology, NFL thickness and ganglion-cell-complex thickness. Normative databases are included. Analysis programs are built in to analyze the ganglion cell layers and the optic nerve, and the system has two scan depth ranges: 2 mm for imaging the macula and 2.3 mm for imaging a tilted disk.

Applications to imaging the anterior segment include corneal and angle imaging. One can calculate the true corneal power (via measurement of inner and outer corneal curvature) and also obtain corneal pachymetry measurements.

NETWORK READINESS

The RTVue has network capability and can connect easily to local networks. This allows desktop review of the images at remote locations even during scanning. More important, this enables back up of the data to local network servers. Of course, the system, like other systems, has internal hard drives that back-up data within the machine. Because the RTVue is network compatible, one can also import fundus images from any camera or SLO system.

In summary, the RTVue system is a user-friendly system that can integrate with local area networking. It is versatile with regard to retina and anterior-segment scanning capability. For retinal scans, there are some unique scanning modes such as the MM5 and the retinal vs choroidal mode. Analysis software is built into the system, together with an extensive normative database. The volumetric analysis in the MM5 program is useful for evaluating macular edema patients; improved registration with the new software for the MM5 analysis increases the power of this system. ■

Jennifer I. Lim, MD, is Professor of Ophthalmology and Director of the University of Illinois Eye and Ear Infirmary in Chicago. Dr. Lim has served as a speaker for OptoVue, but reports no other financial relationships. She may be reached by phone: +1 312 413 0704; or jennylim@uic.edu.



1. Huang D, Swanson EA, Lin CP, et al. Optical coherence tomography. *Science*. 1991;254:1178–1181.
 2. Lim JI, Ou T, Fawzi AA, Hopkins JJ, Gil-Flamer JH, Huang DH. A pilot study of Fourier domain optical coherence tomography of retinal dystrophy patients. *Am J Ophthalmol*. 2008; in press.